

Breast large B-cell lymphoma: An exceptional mammary neoplasm

Salem Bouomrani^{1,2*} and Wided Letaïef^{2,3}

¹Department of Internal medicine, Military Hospital of Gabes, Gabes 6000, Tunisia

²Sfax Faculty of Medicine, University of Sfax, Sfax 3029, Tunisia

³Department of Obstetrics and Gynecology, Regional Hospital of Gabes, Mtorrech 6014, Tunisia

Ameloblastic fibro-odontoma (AFO) is a very rare mixed odontogenic tumor (1-3% of odontogenic tumors). It is a relatively new entity since it was first described as a separate lesion from ameloblastic odontoma in 1967, and introduced in the WHO classification of odontogenic tumors in 1971.

It usually occurs in children and adolescents with an average age of 9 years. The forms with late revelation (after the first two decades of life) remain anecdotal.

The mandible, particularly its posterior part, represents the preferential localization of this tumor. Involvement of the maxilla is exceptional.

This tumor is often limited, encapsulated and evolves very slowly. Aggressive forms with bone destruction and facial deformity are exceptional. Loco-regional recurrences and malignant transformation are also possible.

A 28-year-old patient with no significant pathological history was hospitalized for exploration of a rapidly progressive and painless right maxillary swelling, which had been evolving for three months and caused mild facial dysmorphism. Radiological investigations (panoramic view and CT-scan) showed a large, monogeodic, lytic, and blowing tumor of the right maxilla. This tumor measured 60×10 mm and contained fine calcifications and an included tooth (Figure 1). This tumor had a significant loco-regional extension to the ipsilateral soft tissue of the cheek, nasal cavity, and eye floor (Figure 2). Treatment consisted of complete surgical excision and graft reconstruction. The pathological examination confirmed the diagnosis of AFO.

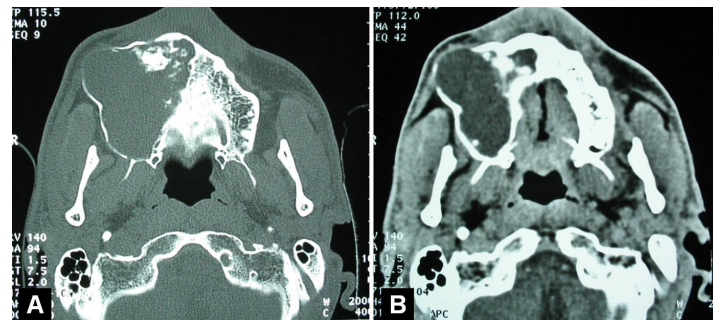


Figure 1. Axial CT-Scan with bone (A) and parenchymal (B) windows: a large and lytic tumor of the right maxilla with areas of calcification and included tooth.

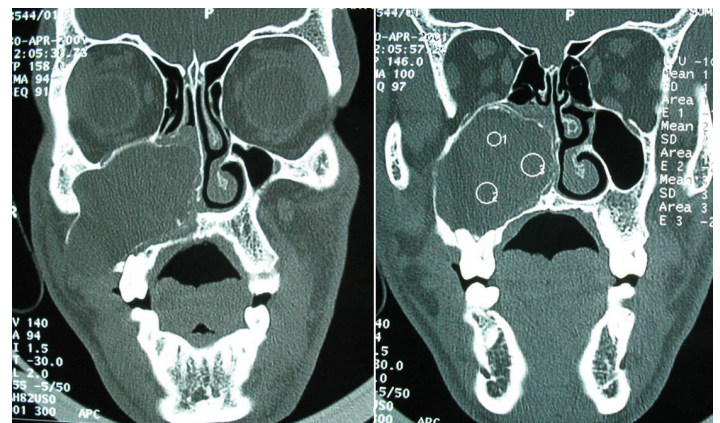


Figure 2. Coronal CT-Scan: a large and lytic tumor of the right maxilla with an important loco-regional extension.

***Correspondence:** Salem Bouomrani, Department of Internal medicine, Military Hospital of Gabes, Gabes 6000, Tunisia, Tel: +00216 98977555; E-mail: salembouomrani@yahoo.fr

Rec: Feb 21, 2019; Acc: Feb 26, 2019; Pub: Feb 28, 2019

J Clin Med Imag. 2019;2(1):14
DOI: gsl.jcmei.2019.00014

Copyright © 2019 The Author(s). This is an open-access article distributed under the terms of the Creative Commons Attribution 4.0 International License (CC-BY).